

Provided for non-commercial research and education use.
Not for reproduction, distribution or commercial use.



This article appeared in a journal published by Elsevier. The attached copy is furnished to the author for internal non-commercial research and education use, including for instruction at the authors institution and sharing with colleagues.

Other uses, including reproduction and distribution, or selling or licensing copies, or posting to personal, institutional or third party websites are prohibited.

In most cases authors are permitted to post their version of the article (e.g. in Word or Tex form) to their personal website or institutional repository. Authors requiring further information regarding Elsevier's archiving and manuscript policies are encouraged to visit:

<http://www.elsevier.com/copyright>



ELSEVIER

www.elsevier.com/locate/ijporl

CASE REPORTS

Association between nasal polyposis, Dubowitz syndrome and hyper-IgE syndrome

Krishnamurti Matos de Araujo Sarmiento Jr.^{a,*}, Shiro Tomita^b,
João Daniel Caliman e Gurgel^c

^a Department of Otolaryngology, Bonsucesso General Hospital, Praia de Botafogo, 422/1106, Botafogo, Rio de Janeiro 22250-040, Brazil

^b Department of Otolaryngology, Federal University of Rio de Janeiro, Brazil

^c Santa Casa de Misericórdia Hospital, São Paulo, Brazil

Received 19 September 2007; received in revised form 14 January 2008; accepted 15 January 2008

Available online 10 March 2008

KEYWORDS

Multiple abnormalities/
genetics;
Craniofacial
abnormalities;
Eosinophilia;
Polyps;
Nasal polyps

Summary Dubowitz syndrome is a rare, autosomal recessive disorder characterized by intrauterine growth retardation, short stature, microcephaly, distinct facial dysmorphism, and psychomotoric retardation. The hyper-immunoglobulin E (hyper-IgE or Job syndrome) is a primary immunodeficiency characterized by recurrent staphylococcal abscesses, recurrent cyst-forming pneumonia, and an elevated serum IgE level of >2000 IU/ml. We present the first case to our knowledge of an association between Dubowitz syndrome, hyper-IgE syndrome, and nasal polyposis (due to allergic fungal sinusitis) in a 14-year-old girl. Eosinophilic inflammatory reaction is the feature present in all three conditions. Unlike most cases of allergic fungal sinusitis, this case was not treated with an initial booster of oral steroids due to the risk of disseminated invasive fungal infection, reported in other cases of hyper-IgE syndrome. The case and its management is presented and discussed.

© 2008 Elsevier Ireland Ltd. All rights reserved.

1. Introduction

Dubowitz syndrome is a rare, autosomal recessive disorder first described in 1965 [1]. It is characterized by intrauterine and post-natal growth retardation, microcephaly, typical facial appearance, varying degrees of mental retardation, and eczematoid skin lesions.

The hyper-IgE syndrome (or Job syndrome) was first described by Buckley in 1972 and consists of a primary immunodeficiency characterized by the clinical triad of recurrent staphylococcal abscesses, recurrent cyst-forming pneumonia and an elevated serum IgE level (usually over 2000 IU/ml) [2].

The causes of both conditions remain unknown. Although one case of an association between Dubowitz and hyper-IgE syndrome has been described³, the presence of nasal polyps has never been reported in either disease. We present the first association of Dubowitz and hyper-IgE syndrome

* Corresponding author. Tel.: +55 21 2480 9622/9617 5788; fax: +55 21 2430 9120.

E-mail address: krishnamurti.sarmiento@gmail.com (K.M.d.A. Sarmiento Jr.).

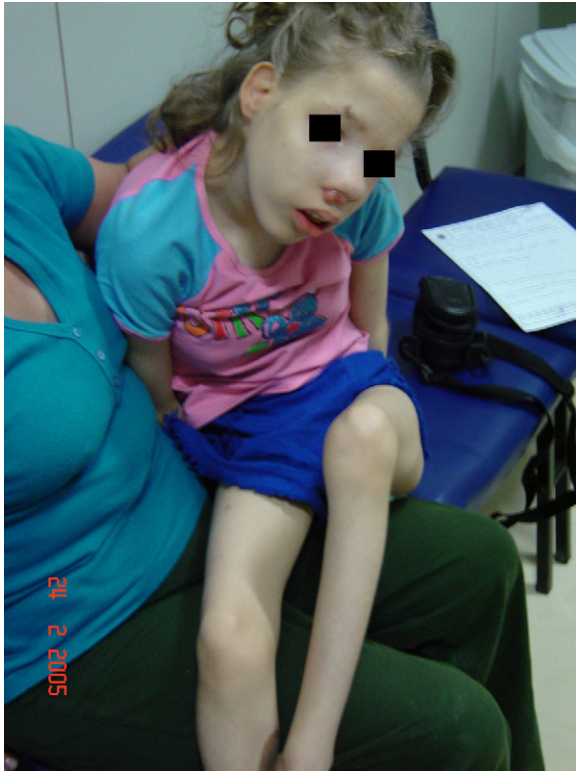

Fig. 1 Physical features of a 14 year-old presenting with severe mental retardation, asthma and recurring upper and lower respiratory infections.

with extensive nasal polyposis, highlighting the management challenges of this unusual case.

2. Case report

A 14-year-old female was brought to the Otolaryngology department of Bonsucesso General Hospital

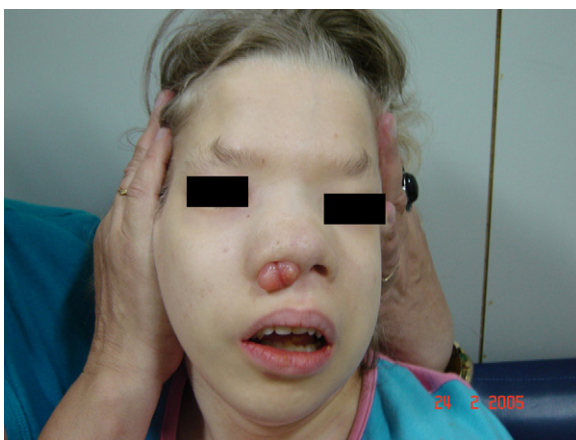

Fig. 2 Facial features: high sloping forehead, narrow bifrontal diameter, hypertelorism, flat supra-orbital ridges, broad nasal bridge and a relatively large mouth.

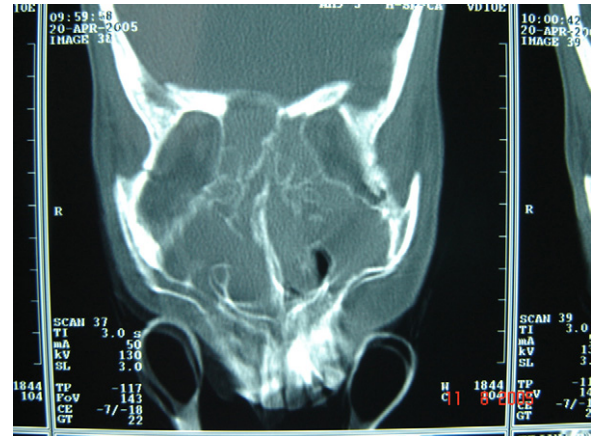

Fig. 3 Coronal scan of computed tomography of the paranasal sinuses showing soft tissue material occupying all sinuses.

due to a growing nasal lesion. The patient was the only child of unrelated parents, born at term by Caesarian section with a birth weight of 2350 g, length of 45 cm and head circumference of 33 cm (all more than 2 S.D. below normal). There was no history of maternal drug or alcohol abuse, X-ray exposure or infection during pregnancy.

The child suffered from severe mental retardation, asthma and recurring upper and lower respiratory infections starting in early childhood, six of them requiring hospitalization. The presence of pneumatoceles was documented in various occasions. Eczematous skin eruptions with frequent flare-ups were present from birth.

Physical examination upon admission revealed a small stature (140 cm), reduced body weight (24 kg), severe scoliosis ($>20^\circ$), leg length discrepancy and hyperextensible joints. Craniofacial features included a high sloping forehead, narrow bifrontal diameter, hypertelorism, flat supra-orbital

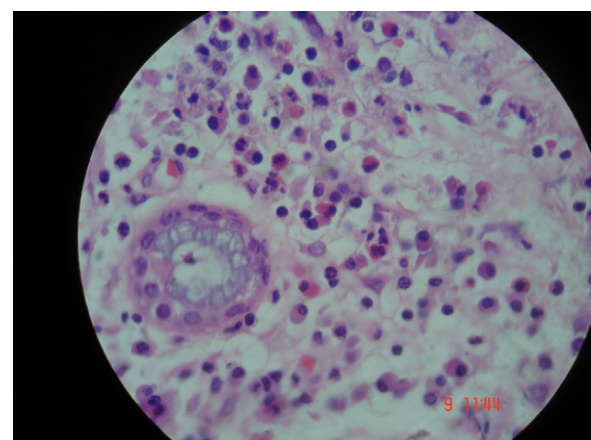


Fig. 4 Hematoxylin/eosin stained slide showing intense eosinophilic reaction.

ridges, asymmetrical ptosis of the eyelids, a broad nasal bridge and a relatively large mouth (Figs. 1 and 2). The psychomotor milestones of development were all retarded.

Both nasal cavities were filled with polyps, the right side being slightly worse, with polyps protruding through the right nostril. There was also abundant purulent discharge. Computed tomography scans showed soft tissue material occupying almost all sinuses (Fig. 3). A subsequent biopsy confirmed nasal polyps with intense eosinophilic reaction (Fig. 4).

Laboratory investigation revealed total white blood cell count of $12,400 \text{ mm}^{-3}$, 25% of eosinophils. Polymorphonuclear chemotaxis measured by the Boyden method was well below normal values. Immunophenotyping of the patient's peripheral mononuclear cells demonstrated normal levels of B cells, CD4+, and CD8+ T cells.

Serum total IgE level was 2750 IU/ml. Other immunoglobulin classes were normal, as were IgG subclasses. Despite previous vaccination, tetanus antibody levels remained low. The total hemolytic complement was normal. RAST tests were used to detect specific IgE antibodies against a number of fungal allergens and were found to be positive to *Bipolaris* sp. and *Curvularia* sp.

The mother was also investigated due to a history of recurrent skin abscesses and eczema. Her total IgE level was 1652 IU/ml. Other findings were eosinophilia of 14% in peripheral blood and abnormal leukocyte chemotaxis.

The patient underwent functional endoscopic sinus surgery, during which a thick brownish material was removed together with the polyps. Microscopic examination revealed allergic mucin, with a large amount of eosinophils, Charcot-Leyden crystals, and the presence of scattered hyphae. Cultures of nasal secretions grew *Bipolaris specifera*. No invasion of fungal hyphae within the mucosa could be demonstrated.

The patient was treated post-operatively with amphotericin-B nasal instillations twice a week and 5 mg/day of prednisolone. After 7 months, the polyps recurred to an extent that justified a second procedure. Twenty months after the second surgery, she developed a minor polyp recurrence, maintaining good nasal patency. She was breathing well and had remarkable improvement of her asthma.

3. Discussion

We present the first case to our knowledge of an association between Dubowitz syndrome, hyper-IgE syndrome, and nasal polyposis (due to allergic fun-

gal sinusitis). The diagnosis of Dubowitz syndrome was made on the basis of intrauterine and post-natal growth retardation, developmental delay, eczematous skin eruptions, microcephaly, and characteristic facial features. The diagnosis of hyper-IgE syndrome was made due to a history of recurrent pneumonia with pneumatoceles, recurrent skin eczemas, defective chemotaxis, eosinophilia, total IgE level over 2000 U/ml and a positive family investigation. The diagnosis of allergic fungal sinusitis with eosinophilic polyposis was made on the presence of polyps, allergic mucin, a positive RAST test against fungal antigens, Charcot-Leyden crystals, and positive culture for *B. specifera* from the nasal mucus.

Although Dubowitz and hyper-IgE syndromes share many clinical features, there has only been one previous report of an association between the two syndromes [3]. Mental retardation, scoliosis, skin eczema, and craniofacial anomalies are present in both syndromes [4–7]. An increased risk for blood malignancies, especially lymphoma, is also reported in both Dubowitz and hyper-IgE syndromes [8,9]. Atopy, moderate elevations of IgE levels, and eosinophilia are found in over 50% of patients with Dubowitz syndrome [10], whereas in hyper-IgE syndrome these findings are the hallmarks of diagnosis.

Eosinophilic inflammation is involved in virtually every case of extensive nasal polyposis. A few syndromes that present with eosinophilia are known to follow with nasal polyps, such as Churg-Strauss and hypereosinophilic syndromes. Nevertheless, nasal polyposis due to allergic fungal sinusitis or any other cause has never been documented in either Dubowitz or hyper-IgE syndromes. There has been a report of a case of hyper-IgE and multiple fungal infections, including recurrent sinusitis that led to two surgical procedures, but no data on polyps or isolation of fungus from sinus material is mentioned in such case [11]. An association between hyper-IgE syndrome and allergic bronchopulmonary aspergillosis, a disease whose underlying mechanisms are strikingly similar to allergic fungal sinusitis, was found in 3 out of 18 patients investigated in one series [12].

Allergic fungal sinusitis is characterized as a non-invasive form of fungal sinusitis, so the use of systemic antifungal medication is considered ineffective [13]. The treatment aims towards reducing the amount of fungus colonizing the nasal cavity and managing the eosinophilic inflammation with oral and topical steroids. In this case, however, there was a major concern that the use of high dose steroids could trigger invasive disease. There are two cases of death in the literature due to disseminated fungal infection in patients with hyper-IgE syndrome and allergic bronchopulmonary aspergil-

losis (whose standard initial treatment is also with a high dose of oral corticosteroids) [12]. For this reason, our patient was given a dose of no more than 5–10 mg of prednisolone a day and an adjunctive treatment option was considered. We believe the use of amphotericin-B topical instillations helped in controlling nasal polyposis by reducing the amount of antigens present in the nasal cavity and thus reducing the inflammatory reaction that leads to polyp formation.

4. Conclusions

This is the first case reported of an association between nasal polyposis, Dubowitz syndrome, and hyper-IgE syndrome. The presence of eosinophilic inflammation, high levels of seric IgE, and eosinophilia are elements present to some extent in all three diseases.

Patients with nasal polyposis, with or without a definite diagnosis of allergic fungal sinusitis, who present other systemic manifestations such as recurrent eczemas, skin abscesses, or craniofacial anomalies should be investigated for hyper-IgE. The standard treatment of extensive polyp disease with high dose steroids might have tragic consequences in such cases.

References

- [1] V. Dubowitz, V. Dubowitz, Familial low birthweight dwarfism with an unusual facies and a skin eruption, *J. Med. Genetics* 42 (1965) 12–17.
- [2] R.H. Buckley, B.B. Wray, E.Z. Belmaker, R.H. Buckley, B.B. Wray, E.Z. Belmaker, Extreme hyperimmunoglobulinemia E and undue susceptibility to infection, *Pediatrics* 49 (1) (1972) 59–70.
- [3] K. Antoniadou, M. Hatzistilianou, G. Pitsavas, C. Agouridaki, F. Athanassiadou, Co-existence of Dubowitz and hyper-IgE syndromes: a case report, *Eur. J. Pediatr.* 155 (5) (1996) 390–392.
- [4] K.R. Swartz, D.K. Resnick, B.J. Iskandar, D. Wargowski, D. Brockmeyer, J.M. Opitz, et al., Craniocervical anomalies in Dubowitz syndrome. Three cases and a literature review, *Pediatr. Neurosurg.* 38 (5) (2003) 238–243.
- [5] M.J. Nowicki, R.B. Peterson, M.J. Nowicki, R.B. Peterson, Dubowitz syndrome and achalasia: two rare conditions in a child, *Clin. Pediatr.* 37 (3) (1998) 197–200.
- [6] A.D. Soyer, J.R. McConnell, A.D. Soyer, J.R. McConnell, Progressive scoliosis in Dubowitz syndrome, *Spine* 20 (21) (1995) 2335–2337.
- [7] B. Grimbacher, S.M. Holland, J.I. Gallin, F. Greenberg, S.C. Hill, H.L. Malech, et al., Hyper-IgE syndrome with recurrent infections—an autosomal dominant multisystem disorder, *N. Engl. J. Med.* 340 (9) (1999) 692–702 (see comment).
- [8] K.T. Moller, R.J. Gorlin, K.T. Moller, R.J. Gorlin, The Dubowitz syndrome: a retrospective, *J. Craniofac. Genet. Dev. Biol.: Suppl.* 1 (1985) 283–286.
- [9] B. Grimbacher, S.M. Holland, J.M. Puck, Hyper-IgE syndromes, *Immunol. Rev.* 203 (2005) 244–250.
- [10] M. Mohrenschlager, A. Beham, D. Abeck, J. Ring, M. Mohrenschlager, A. Beham, et al., Atopic eczema in monozygotic twins with Dubowitz syndrome, *Br. J. Dermatol.* 138 (6) (1998) 1091–1092.
- [11] K. Desai, D.P. Huston, G.R. Harriman, Previously undiagnosed hyper-IgE syndrome in an adult with multiple systemic fungal infections, *J. Allergy Clin. Immunol.* 98 (6 Pt 1) (1996) 1123–1124.
- [12] T.M. Eppinger, P.A. Greenberger, D.A. White, A.E. Brown, C. Cunningham-Rundles, Sensitization to *Aspergillus* species in the congenital neutrophil disorders chronic granulomatous disease and hyper-IgE syndrome, *J. Allergy Clin. Immunol.* 104 (6) (1999) 1265–1272.
- [13] F.A. Kuhn, R. Swain Jr., F.A. Kuhn, R. Swain Jr., Allergic fungal sinusitis: diagnosis and treatment, *Curr. Opin. Otolaryngol. Head Neck Surg.* 11 (1) (2003) 1–5.

Available online at www.sciencedirect.com

