

Title: Endoscopic resection of a sinonasal cavernous hemangioma.

First author:

Krishnamurti Sarmiento Junior (Sarmiento, KJ)

Attending doctor at the Otolaryngology department of Bonsucesso General Hospital.

Co-authors:

João Daniel Caliman Gurgel (Gurgel, JDC)

Senior resident at the Otolaryngology department of Bonsucesso General Hospital.

Klinger Wagner T. da Costa (Costa, KWT)

Senior resident at the Otolaryngology department of Bonsucesso General Hospital.

Eugenio Mello (Mello, E)

Second year resident at the Otolaryngology department of Bonsucesso General Hospital.

Address for correspondence:

Krishnamurti Sarmiento Junior

Praia de Botafogo, 422 / 1106

Rio de Janeiro – RJ – 22250-040

Brazil

Email: krishnamurti@globo.com

Fax Number: 55 – 21 – 2430-9120

Abstract

Hemangiomas are benign endothelial lesions classified as capillary, cavernous or mixed, according to the predominant vascular channels. Cavernous hemangiomas are rare in the sinonasal cavity and traditionally approached externally. We report a case of a 18-year-old man with a cavernous hemangioma occupying the ethmoid and maxillary sinuses, presenting with unilateral nasal obstruction and recurrent sinusitis. The tumor was completely removed endoscopically and there was no signs of recurrence after 18 months follow-up. This is only the second report to date of a cavernous hemangioma of the sinonasal cavity resected endoscopically and the first one to accomplish an *en bloc* resection.

Key words:

Hemangioma, Cavernous / su [Surgery]

Hemangioma / su [Surgery]

Nose Neoplasms / su [Surgery]

Paranasal Sinus Neoplasms / su [Surgery]

Endoscopy

Introduction

Hemangiomas are benign endothelial lesions that are rare in the nose and even rarer in the paranasal sinus. They are classified histologically as capillary, cavernous or mixed, according to the predominant vascular channels within the tumor ¹. Most hemangiomas in the nose are small capillary lesions that arise from the nasal septum or vestibule. Only a few originate from the lateral wall of the nose, with a predominance of cavernous hemangioma, that tend to be larger and more aggressive ².

Cavernous hemangioma may present as an unilateral mass occupying the sinuses and the nose causing epistaxis, progressive nasal obstruction, recurrent sinusitis and very often proptosis and diplopia due to invasion of the orbit. Biopsies may be problematic because of lesion site and risk of uncontrollable bleeding ^{3,4,5}.

Hemangiomas of nose and paranasal sinus have usually been approached externally, but the advances in endoscopic surgery are constantly broadening its indications. This is only the second report to date of a cavernous hemangioma of the sinonasal cavity removed endoscopically, and the first one to aim for a wide resection technique.

Case Report

An 18-year-old man was referred to the Otolaryngology department of the Bonsucesso General Hospital, in Rio de Janeiro, in September 2003, complaining of left facial pain and recurrent purulent nasal discharge for the past year. He also reported progressive nasal obstruction on the left side in the past two months as well as foul smell from the nose. Although objectively asked, he denied major episodes of nose bleeding in the period. He had used various antibiotics in a number of occasions unsuccessfully.

Endoscopic examination revealed a polypoid, smooth, grayish mass occupying the middle meatus and projecting to the nasal fossa. There were no lymph node enlargements in the neck, no facial asymmetry or any other significant findings in the rest of the physical or endoscopic examination.

A CT scan of the sinuses was ordered and showed a mass with soft tissue density occupying the left ethmoid and maxillary sinus, extending to the nasal fossa with marked bone erosion.

Two biopsies were performed under topical anesthesia, but both came inconclusive. There was considerable bleeding during the procedures but easily controlled with local measures. A biopsy under general anesthesia with controlled hypotension was scheduled.

According to the patient's wish and previously settled with the surgical team, we were prepared to convert the procedure to a full open resection according to the immediate pathological result of frozen section. In an adequate sample, the pathologist observed no malignancies and the diagnosis of cavernous hemangioma was suggested. The team decided to proceed with the endoscopic resection.

The surgical technique aimed a large resection, trying to work around the tumor rather than in it. The tumor was carefully pushed medially with cottonoids soaked in adrenalin solution and the dissection followed the sinus limits such as the lamina papyracea and the skull base. An unipolar suction cautery was used with extreme caution. The visualization of the field was considered excellent and the bleeding was kept under control as the surgery progressed slowly. The tumor occupied the anterior and posterior left ethmoid, extending to the anterior wall of the sphenoid sinus and eroding the lateral wall of the nose to reach the maxillary sinus. At the end of the procedure there was clear field with no evidence of residual lesion. The total time of surgery was about two and a half hours. An anterior packing was placed and removed the next day, when the patient was discharged.

The patient was followed with endoscopic examinations monthly for six months and now every three months with no signs of recurrence. He remains asymptomatic after 18 months of follow-up. A recent CT scan was ordered and showed no recurrence. He was offered a septoplasty but refused the procedure because he had no nasal symptoms or breathing complaints.

Discussion

Hemangiomas are classified histologically as capillary, cavernous or mixed, according to the predominant vascular channels. The subtypes also vary in their clinical features. Capillary hemangiomas are more frequent than cavernous, present generally at a younger age and may spontaneously involute². The lobular capillary hemangioma type is commonly misnamed pyogenic granuloma and is a quite common lesion that arise from the skin or mucous membrane, generally in the head and neck³. In contrast, cavernous

hemangiomas typically present in adults, do not undergo spontaneous involution and are more likely to cause compression of surrounding structures^{3,5}.

In the head and neck region, cavernous hemangiomas are more frequent as bone tumors of the skull. Skull hemangiomas represent the second most common site of occurrence and account for 0,2% of all bone tumors and 10% of all primary benign skull tumors^{2,6}. The parietal and frontal bones are most frequently involved. Skull base cavernous hemangiomas are even rarer and the development of such lesions in the nose and sinus are exceptional. There are only about 30 published reports of nasal bone cavernous hemangiomas⁷.

As far as paranasal sinus cavernous hemangiomas are concerned, we were able to find only 21 cases in the literature^{5,8,9,10,11,12,13,14,15,16,17,18,19}: 2 of the middle turbinate⁸, 7 of the ethmoid sinus^{4,8,9,11,12,14}, 6 of the maxillary sinus^{5,13,16,18,19}, 3 of the sphenoid sinus^{2,17}, 1 of the frontal sinus¹⁵ and 2 involving two different sinuses^{10,14}.

The clinical presentation of sinus cavernous hemangioma may be marked by severe epistaxis, but some cases, such as ours, may present only with headaches, facial dysesthesia, nasal obstruction and purulent discharge^{2,11,15}. Orbital proptosis and resulting diplopia are also common features. The age of diagnosis varies from 14 to 71 years old and no sex predominance has been noted^{10,12}.

In surgery, due to the lack of large feeding vessels, capillary hemangiomas are easier to remove, as opposed to the potential bleeding problem expected in the surgery of a cavernous hemangioma.

Endoscopic sinus surgery is constantly pushing its boundaries, with the development of new techniques, technology and the gaining of experience by specialists. Still, large, highly vascular tumors represent a challenge, due to the limitation of the endoscope in providing a wide field vision and the constant danger of losing operability because of profuse bleeding.

Hemangiomas of nose and paranasal sinus have usually been approached externally. This is only the second report to date of a cavernous hemangioma of the sinonasal cavity resected endoscopically. Nevertheless, the two cases have striking differences in their clinical presentations and surgical techniques. In the case previously reported, epistaxis was severe and lead to profound anemia preoperatively³. Surgery was based on removal of cauterized parts of the tumor.

In our case the patient hardly complained of nose bleeding, presenting with an obstructed nose and recurrent sinusitis. Rather than progressively removing cauterized parts of the tumor, we aimed for a wide resection, working around the tumor and isolating it medially in the nose. The use of the monopolar cautery was much more conservative, to avoid lesions in the orbit and dura mater, as we were following the limits of the ethmoid sinus. In this case, the tumor seemed to be larger, occupying completely the ethmoid and maxillary sinuses.

In both cases, nonetheless, surgical bleeding was controlled with careful handling. We believe that apart from the surgical technique, controlled hypotension played a key role in avoiding excessive bleeding in our case. Also in both cases there was no signs of recurrence in the CT scan ordered 18 months after surgery.

We conclude that up to now case reports indicate that endoscopic sinus surgery is effective in complete removal of cavernous hemangiomas of the nose and sinuses.

Fig 1: Pre and post operative CT scans.

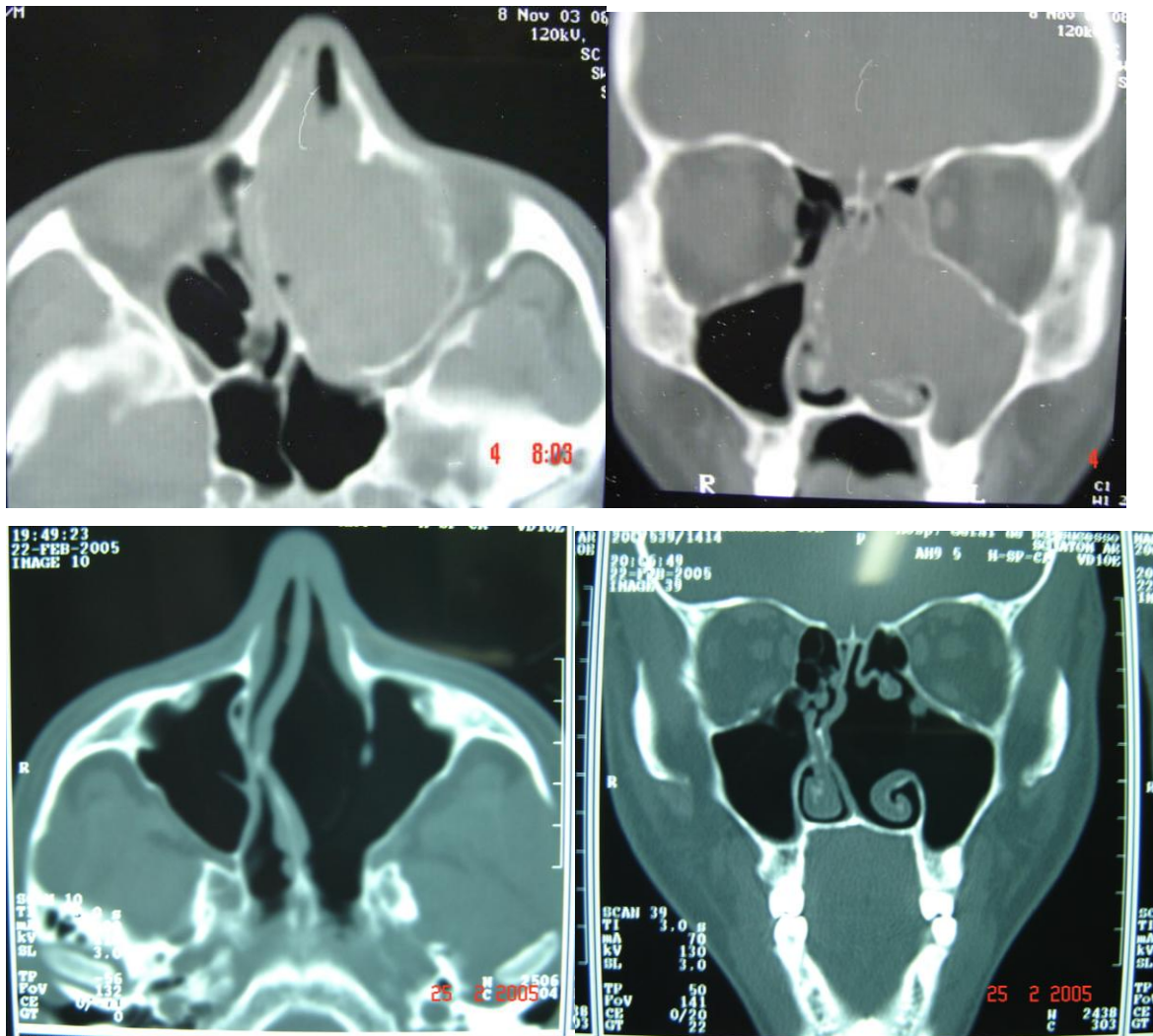
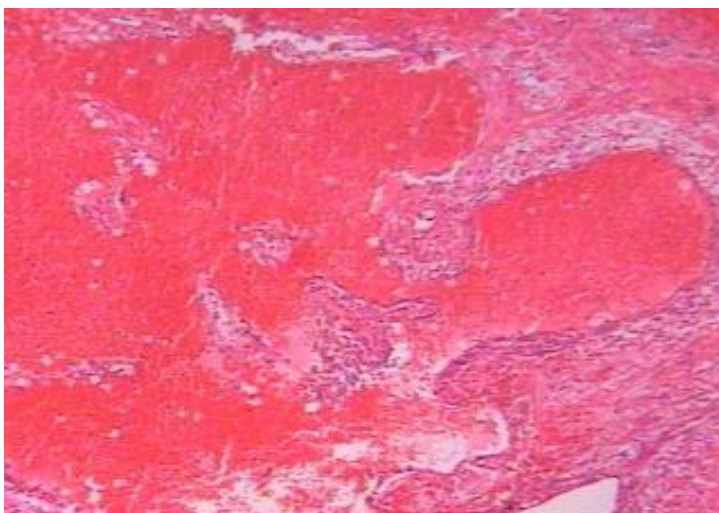


Fig 2 - Histopathological specimen of the patient: HE – 40 X – Cavernous hemangioma



-
- ¹ Murphy MD, Fairbairn KJ, Parman LM, Baxter KG, Paisa MB, Smith WB. Musculoskeletal angiomatous lesions: radiologic-pathologic correlation. *Radiographics* 1995; 15: 893-917.
- ² Dufour H, Fesselet J, Metheus Para, Figarella - Branger D, Grisali F. Cavernous hemangioma of the sphenoid sinus: case report and review of literature. *Surg Neurol* 2001; 55(3): 169- 73.
- ³ Kelley TF. Endoscopic management of an intranasal hemangioma: a case report and literature review. *Otolaryngol Head Neck Surg* Apr 2003; 128(4):595-7.
- ⁴ Steinbach E. An ossifying cavernous hemangioma of the chief nasal cavity and the ethmoid cells. *HNO* 1970; 18:354-6.
- ⁵ Amor Dorado JC, Juiz P, Zubizarret A, Rossi J, Pulpeiro JR. Cavernous hemangioma of the maxillary sinus. *Acta Otorrinolaringol Esp* Mar 1998; 49(2):165-7.
- ⁶ Peterson DL, Murk SE, Story JL. Multifocus cavernous hemangioma of the skull: report of a case and review of the literature. *Neurosurgery* 1992; 30:778-82.
- ⁷ Gourin CG, Millay DJ. Cavernous hemangioma of the nasal bones. *Arch Otolaryngol Head Neck Surg* July 2000; 126(7):902-7.
- ⁸ Handusa AB. *J. Laryng* 1952; 66: 421.
- ⁹ Skalbania J. 1 case of ethmoid hemangioma. *Otolaryng pol* 1965; 19:403.
- ¹⁰ Chatterji P, Sharma ML, Chaterje S. Cavernous haemangioma of fronto-ethmoid region. *J Laryngol Otol* 1969; 83(9):925-33.
- ¹¹ Rozas AF, Arias MJ. Hemangioma cavernoso del Etmóides. *Rev Med Panama* 1988; 13 (1): 54-8.
- ¹² Kim Y, Stearns G, Davidson TM. Hemangioma of the ethmoid sinus. *Otolaryngol Head Neck Surg* Oct 2000; 123(4):517-9.
- ¹³ Kim HJ, Kim JH, Hwang EG. Bone erosion caused by sinonasal cavernous hemangioma: CT findings in two patients. *Am J Neuroradiol* 1995; 15(5):1176-8.

-
- ¹⁴ Kilde JD, Rhee JS, Balla AA, Smith MM, Smith TL. Hemangioma of the sphenoid and ethmoid sinuses: two case reports. *Ear Nose Throat J* Mar 2003; 82(3):217-21.
- ¹⁵ Harar RP, Wolfe KQ, Kumar S, Gatland DJ. Haemangioma of the frontal sinus. . *J Laryngol Otol* Apr 2004; 116(4):296-8.
- ¹⁶ Engels T, Schorner W, Felix R, With H, Johnke V. Cavernous hemangioma of the maxillary sinus. *HNO* Sep 1990; 38(9):342-4.
- ¹⁷ Hayden RE, Luna M, Goepfert H. Hemangiomas of the sphenoid sinus. *Otolaryngol Head Neck Surg* 1980; 88(2):136-8.
- ¹⁸ Milojevic N. Cavernous hemangioma of maxillary sinus (case report). *Med Glas* Apr-May 1970; 24(4):221-2.
- ¹⁹ Bojanic N, Margeta J, Spaic R. Cavernous hemangioma of maxillary sinus. *Srp Arh Celok Lek* 1968; 96(9):915-9.