

ORIGINAL ARTICLE

Retroauricular tympanoplasty and tympanomastoidectomy under local anesthesia and sedation

KRISHNAMURTI MATOS DE ARAUJO SARMENTO JR¹ & SHIRO TOMITA²

¹Otolaryngology Department, Bonsucesso General Hospital and ²Otolaryngology Department, Federal University of Rio de Janeiro, Rio de Janeiro, Brazil

Abstract

Conclusion: Retroauricular tympanoplasty and tympanomastoidectomy under local anesthesia with sedation can be well tolerated by the patient, with minimum discomfort. **Objectives:** To evaluate patient discomfort from pain, body/neck position, noise, and anxiety during tympanoplasties and mastoidectomies performed under local anesthesia with sedation. **Patients and methods:** This was a prospective study of 83 surgeries in 62 patients (28 type I tympanoplasties, 12 tympanoplasties with ossicular reconstruction, 40 canal wall up mastoidectomies, and 3 revision tympanoplasties). Local infiltration used lidocaine 2% with 1:100 000 epinephrine infiltrated in the retroauricular area and from below the pinna in a 'V' pattern. Sedation was achieved with 50 mg of intramuscular promethazine 1 h before surgery and intravenous midazolam (0.03 mg/kg) at the beginning of surgery. Subsequent doses of midazolam were given to maintain adequate sedation, up to 10 mg. The discomfort during surgery was assessed by the patient with a score from 0 to 4 (0 = no discomfort and 4 = extreme discomfort). **Results:** Discomfort due to pain had a mean score of 0.83. Noise discomfort (from drilling and manipulation of instruments) had the lowest mean score (0.70), and discomfort from body and neck position had the highest mean score (1.51).

Keywords: Tympanoplasty, middle ear surgery, mastoid surgery, local anesthesia

Introduction

The safety of general anesthesia has greatly improved in the past decades, making it an attractive choice for most procedures performed by otologists. Its use allows the surgeon to operate on a perfectly still patient, providing a sense of security during the manipulation of delicate middle ear structures. Nevertheless, local anesthesia remains the best option for the patient whenever it provides appropriate analgesia.

Although local anesthesia is often considered for stapes surgery or myringoplasty, the vast majority of surgeons do not consider it for tympanoplasties or mastoidectomies [1,2]. We present a prospective study of 83 retroauricular tympanoplasties and mastoidectomies performed under local anesthesia with sedation, evaluating patient discomfort during the procedures.

Patients and methods

A prospective study was conducted with 62 patients with non-cholesteatomatous chronic otitis media, operated on between January 2006 and December 2007. All patients eligible for the procedures were offered both general and local anesthesia. The decision to use local anesthesia with sedation was made only with the approval of both the surgeon and the patient. Patients who opted for local anesthesia were included in the study only with their informed consent. Patients under 18 years old were excluded.

The authors followed the recommendations of the Practice Guidelines for Sedation and Analgesia by Non-Anesthesiologists, published by the American Society of Anesthesiologists [3]. Moderate sedation (conscious sedation) was the goal. Before surgery, an intravenous line was established. Monitoring consisted of pulse oximetry, continuous

electrocardiography, and non-invasive blood pressure measurement. Supplemental oxygen was given at a flow of 8 L/min using a Hudson mask.

All surgeries were performed in the operating theatre of a general hospital. Although no anesthesiologist was present during the procedure, one was always easily reachable if necessary. A physician from the Otolaryngology Department was assigned to each case to be in charge of sedation and monitoring. Drugs administered and vital signs measured throughout the surgery were recorded. The bag-valve-mask system, laryngoscope, and endotracheal tubes were left prepared in the operating room. The authors (first surgeons to the procedures) were experienced in tracheal intubation and airway management.

At 1 h before surgery, patients received 50 mg of promethazine by intramuscular injection. Immediately before surgery, midazolam was given intravenously at a dose of 0.03 mg/kg, and subsequent doses were used to maintain adequate sedation (closed eyes, but with purposeful response to verbal or tactile stimulation). Cumulative doses over 10 mg were not used.

Lidocaine 2% with 1:100 000 epinephrine was used for local infiltration; about 5 ml was injected in the retroauricular area in a fan pattern (Figure 1). Another 3 ml was infiltrated from below the pinna in a 'V' fashion, reaching the area anterior to the tragus and the anterior surface of the mastoid process (rather deeper). Approximately 1 ml infiltrated the

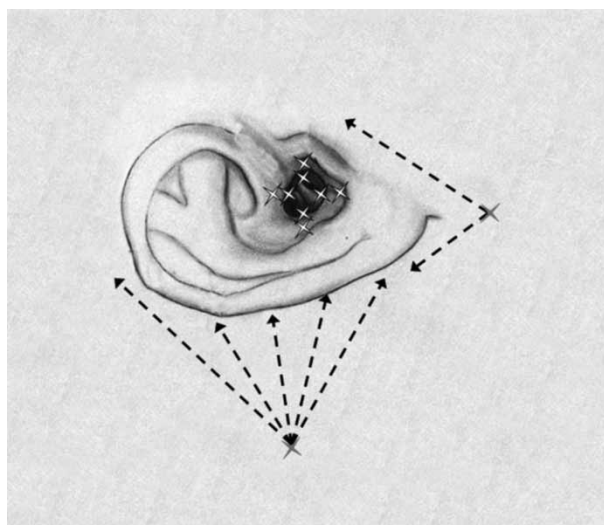


Figure 1. Local anesthetic infiltration technique. About 5 ml of lidocaine 2% with 1:100 000 epinephrine is injected in the retroauricular area in a fan pattern. Another 3 ml is infiltrated in a 'V' fashion, reaching the area anterior to the tragus and the anterior surface of the mastoid process. Approximately 1 ml is infiltrated in the four quadrants of the external ear canal, first at the outer cartilaginous portion and then further medially at the osteocartilaginous junction (white marks).

four quadrants of the external ear canal, first at the outer cartilaginous portion and then further medially at the osteocartilaginous junction.

The day after surgery, patients were asked to score their discomfort for pain, position of the body and neck, noise, and anxiety on a scale from 0 to 4 (0, no discomfort; 1, mild discomfort; 2, moderate discomfort; 3, severe discomfort; 4, extreme discomfort). They were also asked whether they would prefer local anesthesia if they needed ear surgery in the future.

Results

In all, 44 patients had surgery on 1 ear, 18 had surgery on both ears, and 3 revision surgeries were necessary, resulting in a total of 83 procedures under local anesthesia with sedation. Twenty-eight were type I tympanoplasties, 12 were tympanoplasties with ossicular reconstruction, 40 were canal wall up tympanomastoidectomies, and 3 were revision tympanoplasties for closure of lingering tympanic perforation. All surgeries used a retroauricular incision. The mean age was 34.2, with a range of 18–58 years.

Of the patients, 24 had a history including surgery under general anesthesia, and 8 were previously operated on under local anesthesia and sedation for various reasons. The rest had no history of surgery.

Of the 62 patients, 51 (82%) declared that they would prefer a second ear surgery to also be done under local anesthesia if there was a need, which actually happened in 18 cases for the contralateral ear and in 3 cases for revision surgery.

The mean surgical time (from infiltration to skin closure) was 108 min, ranging from 38 to 136 min. The mean time the patient stayed on the operating table was 126 min, ranging from 52 to 160 min.

The scores for discomfort are presented in Table I. All parameters had a mean score between 'no discomfort' and 'mild discomfort' (i.e. between 0 and 1), with the exception of the position of the body and neck, which had a mean score of 1.51. Noise from the surgical instruments (including drilling) scored the lowest, with a mean value of 0.70.

Transient facial paresis, probably due to lidocaine infiltration of the anterior surface of the mastoid tip, was seen in four patients and lasted for a few hours after surgery.

Discussion

Although it has long been known that ear surgery can be carried out under local anesthesia, only a small number of surgeons feel comfortable using this technique for tympanoplasties or tympanomastoi-

Table I. Scores for discomfort from pain, position of the body and neck, noise, and anxiety.

Parameter	Grade					Mean value (0–4)
	0	1	2	3	4	
Pain	44	23	8	2	6	0.83
Position of body and neck	21	23	20	14	5	1.51
Noise	45	26	6	4	2	0.70
Anxiety	36	25	18	3	1	0.89

Grade 0, no discomfort; 1, mild discomfort; 2, moderate discomfort; 3, severe discomfort; 4, extreme discomfort.

dectomies. Retroauricular approaches and drilling are associated with long, laborious surgeries and raise concerns that patients may not tolerate the noise and discomfort. Nevertheless, a few papers have presented data challenging this intuitive association [4–6].

In our hospital, it is undeniable that the shortage of staff in the Anesthesiology Department played an important role in our interest in the use of local anesthesia for ear surgery. However, there are many other advantages to the technique, such as less bleeding, cost-effectiveness, postoperative analgesia, faster mobilization of the patient, and the ability to test hearing intraoperatively [7].

It has been our experience that retroauricular surgery under local anesthesia, even when drilling is required, poses no greater discomfort to the patient. Excellent analgesia can be achieved by blocking the branches of the great auricular nerve (retroauricular infiltration) and the tympanic branch of the auriculotemporal nerve (V-shaped infiltration). The mastoid cells are devoid of sensation, with the exception of the outer periosteum and, to a lesser degree, the inner mucoperiosteum, so that drilling is not painful for the patient.

The sensation of pain depends not only on the extent of surgical trauma and infiltration technique but also on a patient's emotional status and previous experiences. Careful explanation of the procedure in the preoperative consultation is important to reduce anxiety. The patient should understand that local anesthesia provides analgesia but does not eliminate tactile sensations in the infiltrated area, which means one would be able to feel the manipulation of tissues and the noise of the instruments, but not pain.

Surgeons who are used to general anesthesia, however, must also learn not to get angry or alarmed when patients move their heads or bodies slightly during surgery. Instead of a harsh reprimand, it is prudent to ask the patient whether he or she is feeling any pain and even to allow him or her to change position, as long as it does not compromise the surgical field. The fact that we were less tolerant in the beginning with patients' changes in body position

might have resulted in the slightly higher score for the body and neck discomfort that we found.

In the case of open mastoidectomies (canal wall down), we used the Zurich technique, which consists of complete exenteration of mastoid cells, removal of the mastoid tip, partial obliteration of the cavity with a musculocutaneous flap, and wide meatoplasty [8]. This operation takes an average of 4 h in our hands, and we consider it unsuitable for local anesthesia due its length.

Conclusion

Retroauricular tympanoplasties and tympanomastoidectomies under local anesthesia with sedation can be well tolerated by the patient, with minimum discomfort.

Declaration of interest: The authors report no conflicts of interest. The authors alone are responsible for the content and writing of the paper.

References

- [1] Yung MW. Local anaesthesia in middle ear surgery: survey of patients and surgeons. *Clin Otolaryngol Allied Sci* 1996;21: 404–8.
- [2] Edussuriya B, Goonasekera CD, Rajapakse M, Rajapakse VP, Jayasooriya D. Middle ear surgery under local anaesthesia and sedation. *Ceylon Med J* 1997;42:75–7.
- [3] American Society of Anesthesiologists Task Force on Sedation and Analgesia by Non-Anesthesiologists. Practice guidelines for sedation and analgesia by non-anesthesiologists. *Anesthesiology* 2002;96:1004–17.
- [4] Lancer JM, Fisch U. Local anaesthesia for middle ear surgery. *Clin Otolaryngol Allied Sci* 1988;13:367–74.
- [5] Caner G, Olgun L, Gultekin G, Aydar L. Local anesthesia for middle ear surgery. *Otolaryngol Head Neck Surg* 2005;133: 295–7.
- [6] Vicente Gutierrez U, Garcia Pourrinos F. Locoregional anesthesia for external ear surgery and postoperative analgesia. *Rev Esp Anestesiol Reanim* 2000;47:442–6.
- [7] Andreassen UK, Larsen CB. Anesthesia in ear surgery. A resource economical analysis and patient assessment of general anesthesia versus local anesthesia in ear surgery. *Ugeskr Laeger* 28 1990;152:1595–7.
- [8] Fisch U, May J. Tympanoplasty, mastoidectomy, and stapes surgery, 3rd edn. Berlin: Thieme, 1994.