

Mouth breathing: Adverse effects on facial growth, health, academics, and behavior

By Yosh Jefferson, DMD, MAGD

Featured in *General Dentistry*, January/February 2010

Pg. 18-25

Posted on Friday, January 08, 2010



The vast majority of health care professionals are unaware of the negative impact of upper airway obstruction (mouth breathing) on normal facial growth and physiologic health. Children whose mouth breathing is untreated may develop long, narrow faces, narrow mouths, high palatal vaults, dental malocclusion, gummy smiles, and many other unattractive facial features, such as skeletal Class II or Class III facial profiles. These children do not sleep well at night due to obstructed airways; this lack of sleep can adversely affect their growth and academic performance. Many of these children are misdiagnosed with attention deficit disorder (ADD) and hyperactivity.

It is important for the entire health care community (including general and pediatric dentists) to screen and diagnose for mouth breathing in adults and in children as young as 5 years of age. If mouth breathing is treated early, its negative effect on facial and dental development and the medical and social problems associated with it can be reduced or averted.

Received: February 11, 2009

Accepted: May 5, 2009

The importance of facial appearances in contemporary society is undeniable. Many studies have shown that individuals with attractive facial features are more readily accepted than those with unattractive facial features, providing them with significant advantages.¹⁻⁶ However, many health care professionals (as well as the public) feel that individual facial features are the result of genetics and therefore cannot be altered or changed—in other words, the genotype ultimately controls the phenotype. However, more and more studies are showing that environmental factors may play a significant role in facial and dental development and may alter the phenotype.

In the most definitive experiments to study the relationship between airway obstruction and craniofacial growth, latex plugs were inserted in the nasal openings of young rhesus monkeys. The sudden change from nasal respiration to oral respiration caused changes in the function of the masticatory muscles.⁷ The first noticeable changes were functional, as the animals altered their neuromuscular pattern of activity to breathe. With their nasal respiration blocked, individual monkeys achieved respiration in different ways; some postured their mandible with a downward and backward (retrusive) opening rotation, while others lowered and raised their mandibles rhythmically with each breath. Still others postured their jaws in a downward and forward (protrusive) position. Each in its own way was able to respire; however, all did so via mouth breathing.⁷

Harvold reported that the distance from the nasion to the chin increased significantly in mouth breathing animals; in addition, the distance from the nasion to the hard palate increased, due to the downward displacement of the maxilla. The lower border of the mandible became steeper and the gonial angle increased. It is significant that these animals developed long faces.⁷

A change in breathing pattern led to a variety of skeletal and dental deformities in an animal that ordinarily does not develop malocclusions and facial abnormalities under natural conditions. It was not the change in breathing pattern that caused the malocclusion and the various forms of facial disharmony; rather, the ultimate facial and dental abnormalities depended on which of the three forms of respiration the animal developed. Animals that rhythmically lowered and raised their mandibles with each breath developed a Class I open bite and a skeletal Class I open bite (that is, long faces). Animals that rotated their mandibles in a posterior and inferior direction developed a Class II malocclusion and a skeletal Class II profile. The animals whose mandible maintained an anterior position developed a Class III malocclusion and a skeletal Class III profile.⁷

The literature has shown a correlation between mouth breathing and abnormal facial growth in humans.

McNamara found a relationship between upper airway obstruction and deviant facial growth.⁸ Bresolin *et al* studied 45 North American Caucasians (30 chronic mouth breathers and 15 nasal breathers) of both sexes (ranging in age from 6–12 years) and found that mouth breathers had longer faces with a narrower maxilla and

retrognathic jaws.^{9,10} Trask *et al* studied 64 children medically, dentally, and cephalometrically: 25 allergic children who were mouth breathers, 25 nasal breathing siblings, and 14 nasal breathing control subjects. The authors found that the allergic children had longer and more retrusive faces than the control group.¹¹

The patient in Figure 1 illustrates how untreated mouth breathing in children can cause abnormal myofunction. Left untreated, this condition can adversely affect normal facial growth and dental development. At age 6, the child had normal facial features; however, her mouth breathing went untreated. By age 9, the child had developed a long, narrow face and severe dental malocclusion. She was successfully treated using functional appliance therapy.



Fig. 1. *Left:* A 6-year-old girl who was a severe mouth breather. *Right:* The same patient at age 9, with abnormal facial growth and dental malocclusion. (Photographs courtesy of Dr. John Mew.)

Mouth breathing and its negative impact on health

In addition to various types of abnormal facial growth and dental malocclusions, many other medical problems can be attributed to mouth breathing. First and foremost, nasal respiration (which is produced in the nasal sinuses) is essential for the production of nitric oxide.¹²⁻¹⁴ Nitric oxide inhaled via nasal respiration has been shown to increase oxygen exchange efficiency and increase blood oxygen by 18%, while improving the lungs' ability to absorb oxygen.^{15,16} Nitric oxide also is a strong vasodilator and brain transmitter that increases oxygen transport throughout the body and is vital to all body organs.¹⁷ Nitric oxide is crucial to overall health and the efficiency of smooth muscles, such as blood vessels and the heart.¹⁸⁻²⁵ Many other health benefits have been attributed to nitric oxide.²⁶⁻²⁸

Nasal respiration provides the most efficient mechanism for introducing oxygen into the lungs and body for overall health. Mouth breathers have a lower oxygen concentration in their blood than those who have optimal nasal respiration; low oxygen concentration in the blood has been associated with high blood pressure and cardiac failures.²⁹⁻³²

The negative impact of sleeping disorders on growth and development has been substantiated in many studies. Many children with sleep disorders are often well below their peers in terms of height and weight.³³⁻³⁸

Other major issues beyond abnormal facial and dental development also have been associated with mouth breathing. Studies have shown that upper airway obstruction/mouth breathing can cause sleep disorders and sleep apnea.³⁹⁻⁴⁴ Studies have shown that children with sleep disorders have problems paying attention in school, are often tired, and may exhibit behavior problems; many of these children often are misdiagnosed with attention deficit hyperactivity disorder (ADHD).⁴⁵⁻⁵⁰ The current standard of care for children, adolescents, and

adults with ADHD is medication with such stimulant drugs as Adderall (Shire US Inc.) or Ritalin (Novartis Pharmaceuticals).⁵¹⁻⁵³ These medications have raised concerns about reduced height and weight, cardiovascular effects, tics, evidence of carcinogenic and reproductive effects, and substance abuse.⁵⁴⁻⁶¹

ADHD is the most commonly diagnosed behavioral disorder in children; however, many of these children have sleep disorders and are being misdiagnosed.⁶² In the author's opinion, the ideal treatment for these children involves treating the blocked airway, allowing the child to breathe through the nose rather than the mouth. Mouth breathing irritates the mucosa, and these children often will have swollen tonsils and adenoids, one of the major causes of upper airway obstruction, sleep disorders, and sleep apnea.^{63,64} Surgical removal of swollen tonsils and adenoids is highly recommended when they negatively affect sleep.⁶⁵⁻⁶⁸ With surgical removal of swollen tonsils and adenoids, many of these children who were misdiagnosed with ADHD have shown marked improvement in behavior, attentiveness, energy level, academic performance, and growth and development; in addition, nocturnal enuresis was corrected.⁶⁹⁻⁷⁵

The dentist's role in the diagnosis and treatment of mouth breathing

General and pediatric dentists may be in the best position to screen and treat patients who suffer from upper airway obstruction/mouth breathing. Dentists usually see patients on a regular basis every six months, and swollen tonsils can be easily detected by using a mouth mirror to look at the back of the patient's throat. All patients—children, adolescents, and adults—should be screened for upper airway obstruction. All patients who have some or all of the conditions listed in the table (Fig. 2–5) should be examined for sleep disorders or sleep apnea.

Table. Signs of possible sleep apnea or sleeping disorder.

Long, narrow faces in older children, adolescents, and adults (sometimes not seen in younger children, since abnormal facial growth has not yet been expressed) (Fig. 2)

Adenoid facies that include pinched nostrils, open mouth, shortened upper lip, vacant and dull expression, and allergic shiner under the eyes (Fig. 3)

Narrow palate, high palatal vault, and dental crowding (Fig. 4)

Swollen tonsils (Fig. 5)

Small and slight stature for children; heavy and obese for adults (a neck circumference of ≥ 17 in. for men or ≥ 16 in. for women is an indication of potential sleep apnea)

Patients who snore or partially snore during sleep

Patients who sleep with their mouth open

Patients who are tired or irritable during the day

Patients who experience behavior problems

Patients who are unable to concentrate or do poorly in school

Patients who are easily winded from sports activities

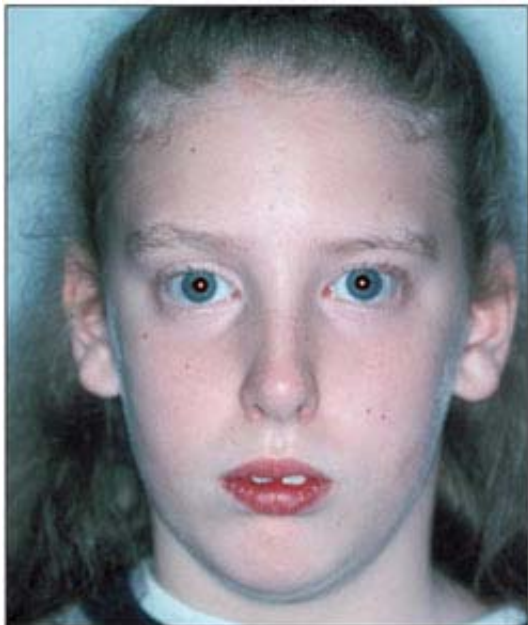

Fig. 2. A patient with a long, narrow face.

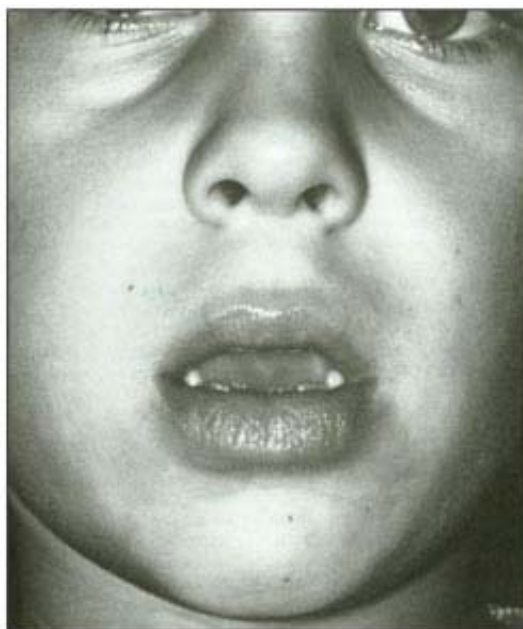


Fig. 3. The patient in Figure 2, with adenoid facies. (Photo courtesy of James F. Garry, DDS.)

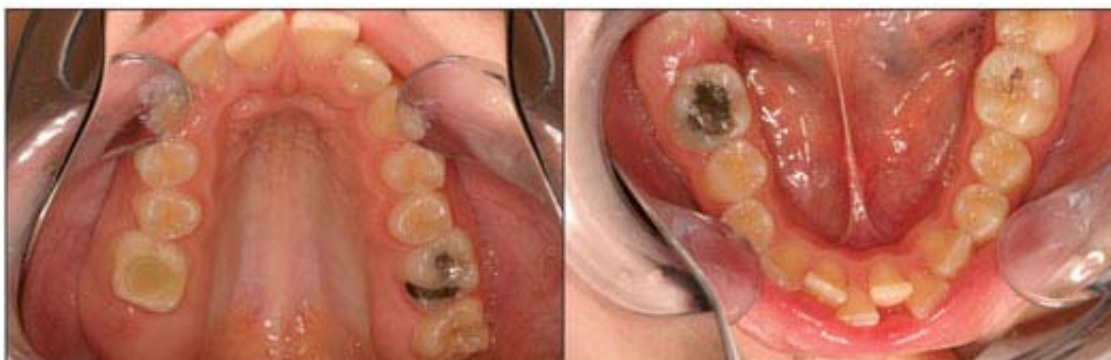

Fig. 4. An example of a child with a narrow palate, high palatal vault, and dental crowding due to mouth breathing.

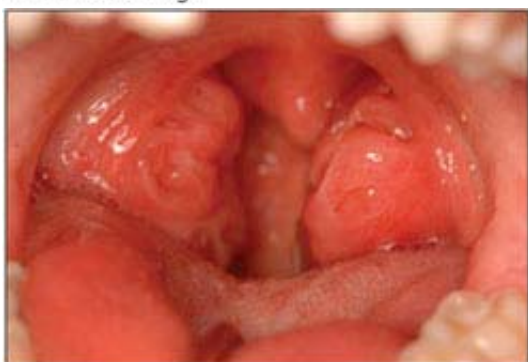

Fig. 5. An example of swollen tonsils, usually found in mouth breathers.

At present, the author believes that the diagnosis and treatment of mouth breathing (and all of its associated medical, social, and behavioral problems) is best managed by using a multidisciplinary approach involving pediatricians, physicians, dentists, and ear-nose-throat (ENT) specialists. Using the clinical observations cited in the table, pediatricians, physicians, and dentists are the primary care providers who can diagnose mouth breathing and sleep disorder problems; these patients should be referred to an ENT specialist for further evaluation and treatment. As previously noted, surgically removing swollen tonsils and adenoids has improved nasal respiration, sleep, behavior problems, and academic performance. Based on the author's experience, many athletically inclined children will actively seek treatment when they understand that it will improve their respiration and enhance their athletic performance.

upper airway obstruction, patients who also exhibit narrow palates and high palatal vaults may require additional dental treatment. These conditions result in narrow and compressed sinuses, which can inhibit nasal respiration.⁷⁶⁻⁷⁸

This second line of treatment should be provided by dentists, who can correct facial and dental abnormalities with functional appliances. Various functional appliances, such as Frankel II and Herbst, have been used to open retrognathic mandibles, which tend to close the pharyngeal airways.⁷⁹⁻⁸² These patients need palatal expansion to open the nasal sinuses, which will allow for more efficient nasal respiration. According to the literature, a combined therapy of adenotonsillectomy and palatal expansion significantly improved sleep and nasal respiration while alleviating the symptoms of ADHD.⁸³⁻⁸⁸

Case report

The author has experienced success in alleviating sleep disorders and ADHD by using the diagnostic screening for mouth breathing and the multidisciplinary treatment protocol described in this article. Some of these patients have experienced improvements in their moods, growth and development, school grades, energy, and athletic performance as well as an alleviation of night time enuresis. No case has been more dramatic, however, than this one.

A 5-year-old boy was seen by a pediatric dentist who understood the problems associated with mouth breathing. The dentist immediately referred him to an ENT specialist, and his tonsils and adenoids were surgically removed; at that point, the child was referred to the author for orthodontic treatment (Fig. 6). The patient was skeletal Class II (mandibular retrognathic), dental Class II, division 1 (Fig. 7). An occlusal view showed minimal crowding; however, the boy had moderately narrow maxillary and mandibular arches with a high palatal vault (Fig. 8).



Fig. 6. A boy aged 5 years, 11 months, with adenoid facies.

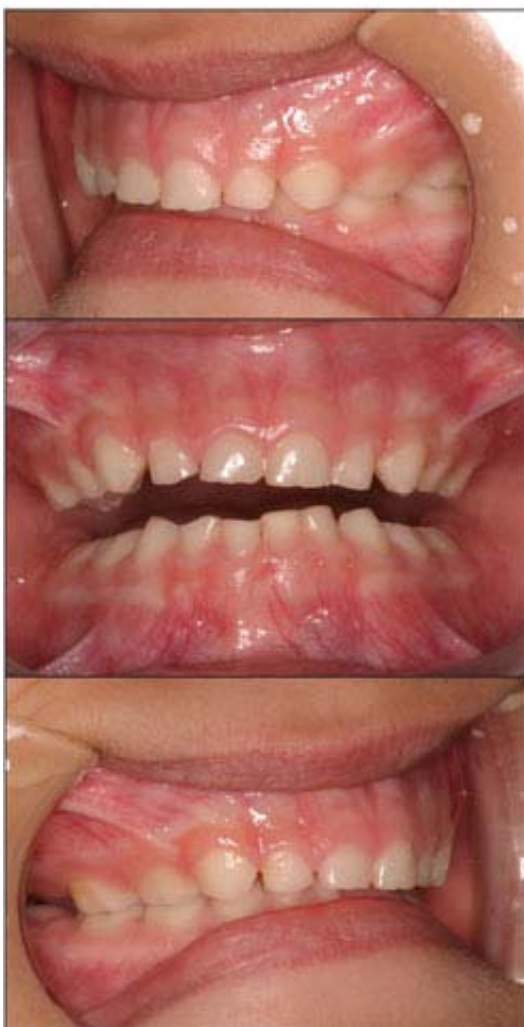

Fig. 7. An intraoral photograph of the patient in Figure 6.

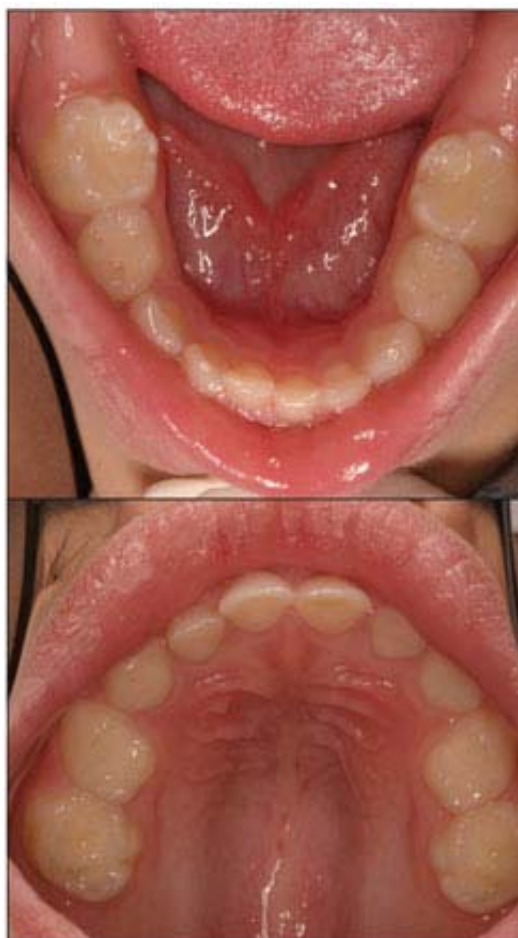

Fig. 8. An occlusal view of the patient in Figure 6. Note that the maxillary and mandibular arches are moderately narrow and the palatal vault is high.

A diagnostic screening revealed that the patient was too young to have developed a long, narrow face; however, he had the typical “adenoid facies” that is indicative of upper airway obstruction/mouth breathing and sleep disorder. In addition, the patient’s height and weight were well below average for his age. In the patient’s health questionnaire, his mother noted that he slept with his mouth open, he tired easily during the day and was easily winded, and he had severe behavior problems in school, throwing temper tantrums to the point where his teacher would have to call on the patient’s older brother to calm him. The patient was unable to concentrate in school and was failing most of his subjects.

Since the patient had a moderately narrow palate and high palatal vault, palatal expansion was indicated. Maxillary and mandibular Schwarz appliances were used to expand both the maxillary and mandibular arches during Phase I removable appliance therapy (Fig. 9).

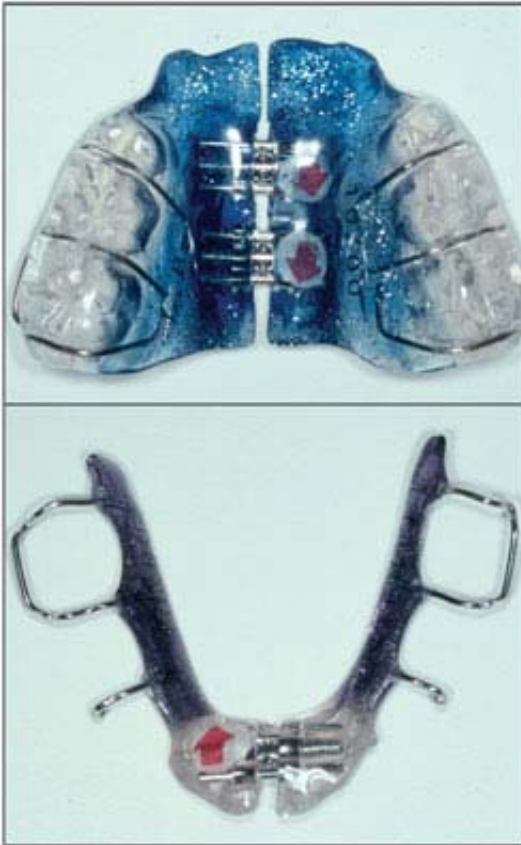


Fig. 9. Schwarz expansion devices made for the patient's maxillary and mandibular arches.

Figures 10–12 show facial photographs (including intraoral dentition) taken after approximately two years of expansion therapy. The patient was slightly overexpanded and there are diastema in the maxillary anterior region, although these can be corrected easily during the Phase II fixed appliance therapy.

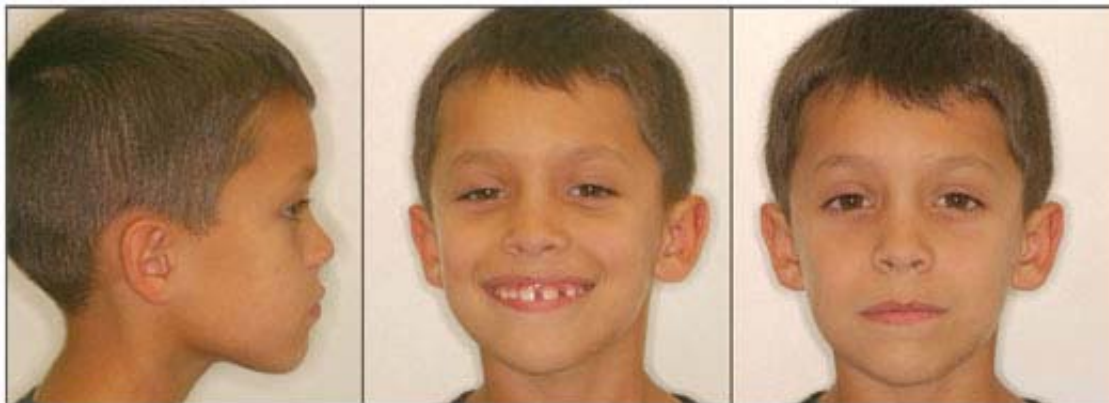

Fig. 10. The patient in Figure 6, 19 months after the start of Schwarz appliance therapy.

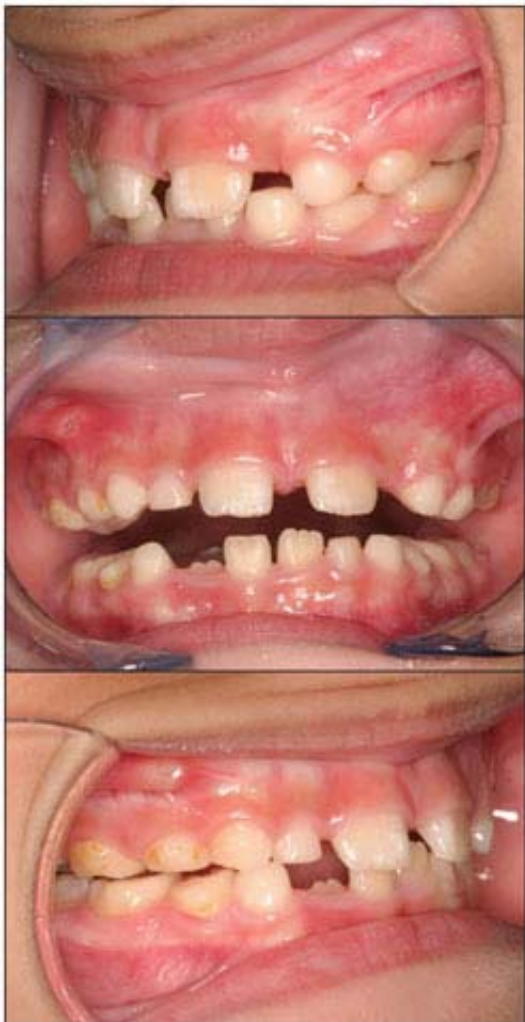

Fig. 11. An intraoral photograph of the patient in Figure 6, taken 19 months after the initial insertion, showing some anterior diastema due to slight overexpansion.

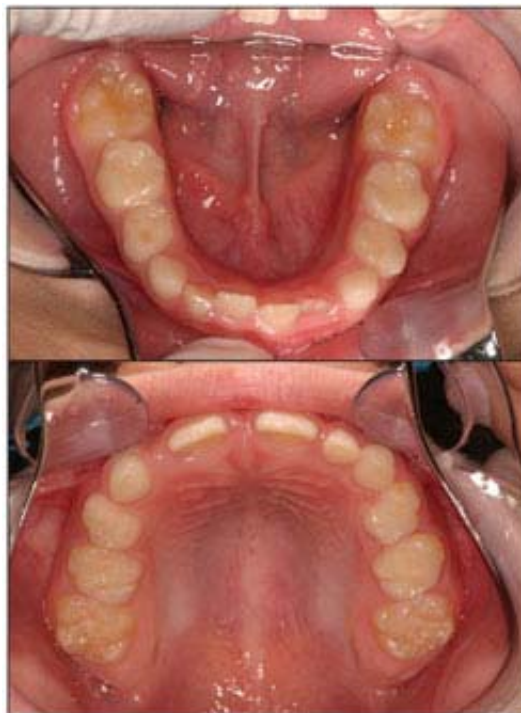

Fig. 12. The maxillary and mandibular arches of the patient in Figure 6, 19 months after the initial insertion.

Even after only one year of expansion therapy, the patient's mother claimed to observe significant improvements in many areas, noting that the patient sleeps better, has a better disposition, is more energetic and willing to participate in activities, stopped bed wetting within seven months after the start of therapy, experienced a significant growth spurt, and had a better appetite and improved speech. In addition, while the patient had been failing most of his subjects, he recently took a standardized achievement test used in the U.S. to assess K–12 student achievement and posted combined reading, language, and math scores in the 99th percentile.

Summary

Sleep disorder/sleep apnea is a widespread and prevalent condition that has profound effects on the health and well-being of all who suffer from it. Many patients may develop emotional and psychological problems in addition to physical and medical problems. Without treatment, these individuals will place an enormous financial burden on the health care system and on society as a whole. These patients can be treated successfully by using the multidisciplinary approach discussed in this article.

Although a preponderance of studies show the direct correlation between mouth breathing and abnormal facial growth and sleep disorder/sleep apnea, not enough information is available about this correlation. This article is presented in the hope that both health care professionals and the public will become more knowledgeable about and more vigilant in assessing mouth breathing in children and adults, thus alleviating the many emotional, physical, and psychological problems associated with this condition.

Author information

Dr. Jefferson is in private practice in Mount Holly, New Jersey, and is a member of the General Dentistry Advisory Board.

References

1. Hammermesh DS, Biddle JE. Beauty and the labor market. *Am Econ Rev* 1994;84(5):1174-1194.
2. Hope DA, Mindell JA. Global social skill ratings: Measures of social behavior or physical attractiveness? *Behav Res Ther* 1994;32(4):463-469.
3. Solnick SJ, Schweitzer ME. The influence of physical attractiveness and gender on ultimatum game decisions. *Organ Behav Hum Decis Process* 1999;79(3):199-215.
4. Salvia J, Sheare JB, Algozzine B. Facial attractiveness and personal-social development. *Abnorm Child Psychol* 1975;3(3):171-178.
5. Mathes EW, Kahn A. Physical attractiveness, happiness, neuroticism, and self-esteem. *J Psychol* 1975;90 (1st Half):27-30.
6. Ritts V, Patterson MI, Tubbs ME. Expectations, impressions, and judgments of physically attractive students: A review. *Rev Ed Research* 1992; 62(4):413-426.
7. McNamara JA Jr, Brudon WL. *Orthodontics and dentofacial orthopedics*, ed. 3. Ann Arbor, MI: Needham Press;2004:123-125.
8. McNamara JA. Influence of respiratory pattern on craniofacial growth. *Angle Orthod* 1981;51(4):269-300.
9. Bresolin D, Shapiro PA, Shapiro GG, Chapko MK, Dassel S. Mouth breathing in allergic children: Its relationship to dentofacial development. *Am J Orthod* 1983;83(4):334-340.
10. Bresolin D, Shapiro GG, Shapiro PA, Dassel SW, Furukawa CT, Pierson WE, Chapko M, Bierman CW. Facial characteristics of children who breathe through the mouth. *Pediatrics* 1984;73(5):622-625.
11. Trask GM, Shapiro GG, Shapiro PA. The effects of perennial allergic rhinitis on dental and skeletal development: A comparison of sibling pairs. *Am J Orthod Dentofacial Orthop* 1987;92(4):286-293.
12. Jiang J, Malavia N, Suresh V, George SC. Nitric oxide gas phase release in human small airway epithelial cells. *Respir Res* 2009;10(1):3.
13. Lundberg JO, Farkas-Szallasi T, Weitzberg E, Rinder J, Lidholm J, Anggaard A, Hokfelt T, Lundberg JM, Alving K. High nitric oxide production in human paranasal sinuses. *Nat Med* 1995;1(4):370-373.
14. Djupesland PG, Chatkin JM, Qian W, Haight JS. Nitric oxide in the nasal airway: A new dimension in otorhinolaryngology. *Am J Otolaryngol* 2001;22(1):19-32.
15. Shibata M, Yamakoshi T, Yamakoshi KI. Physiological role of nitric oxide in oxygen consumption by anterior wall. *Conf Proc IEEE Eng Med Biol Soc* 2008;1:1389-1392.
16. Lundberg JO, Settergren G, Gelinder S, Lundberg JM, Alving K, Weitzberg E. Inhalation of nasally derived nitric oxide modulates pulmonary function in humans. *Acta Physiol Scand* 1996;158(4):343-347.
17. Page DC. *Your jaws your life*. Baltimore: Smile-Page Publishing;2003.
18. Bian K, Doursout MF, Murad F. Vascular system: Role of nitric oxide in cardiovascular diseases. *J Clin Hypertens (Greenwich)*. 2008;10(4):304-310.
19. Feletou M, Tang EH, Vanhoutte PM. Nitric oxide the gatekeeper of endothelial vasomotor control. *Front Biosci* 2008;13:4198-4217.
20. Sumino H, Sato K, Sakamaki T, Masuda H, Nakamura T, Kanda T, Nagai R. Decreased basal production of nitric oxide in patients with heart disease. *Chest* 1998;113(2):317-322.
21. Rush JW, Denniss SG, Graham DA. Vascular nitric oxide and oxidative stress: Determinants of endothelial adaptations to cardiovascular disease and to physical activity. *Can J Appl Physiol* 2005;30(4):442-474.
22. Danson EJ, Paterson DJ. Cardiac neurobiology of nitric oxide synthases. *Ann N Y Acad Sci* 2005; 1047:183-196.
23. Cooke JP. The pivotal role of nitric oxide for vascular health. *Can J Cardiol* 2004;20 Suppl B:7B-15B.
24. Mineo C, Shaul PW. HDL stimulation of endothelial nitric oxide synthases: A novel mechanism of HDL action. *Trends Cardiovasc Med* 2003;13(3):226-231.
25. Trochu JN, Bouhour JB, Kaley G, Hintze TH. Role of endothelium-derived nitric oxide in the regulation of cardiac oxygen metabolism: Implications in health and disease. *Circ Res* 2008; 87(12):1108-1117.
26. Ricciardolo FL, Sterk PJ, Gaston B, Folkerts G. Nitric oxide in health and disease of the respiratory system. *Physiol Rev* 2004;84(3):731-765.
27. Albert J, Schedin U, Lindqvist M, Melcher A, Hjemdahl P, Frostell C. Blockade of endogenous nitric oxide production results in moderate hypertension, reducing sympathetic activity and shortening bleeding time in healthy volunteers. *Acta Anaesthesiol Scand* 1997;41(9):1104-1113.
28. Phillips L, Toledo AH, Lopez-Neblina F, Anaya-Prado R, Toledo-Pereyra LH. Nitric oxide mechanism of protection in ischemia and reperfusion injury. *J Invest Surg* 2009;22(1):46-55.
29. Tanigawa T, Tachibana N, Yamagishi K, Muraki I, Kudo M, Ohira T, Kitamura A, Sato S, Shimamoto T, Iso H. Relationship between sleep-disordered breathing and blood pressure levels in community-based samples of Japanese men. *Hypertens Res* 2004;27(7):479-484.
30. Andreas S, von zur Muhlen F, Stevens J, Kreuzer H. Nocturnal oxygen and hypercapnic

ventilatory response in patients with congestive heart failure. *Respir Med* 1998;92(3):426-431.

31. Agostoni P, Bussotti M, Cattadori G, Margutti E, Contini M, Muratori M, Marenzi G, Fiorentini C. Gas diffusion and alveolar-capillary unit in chronic heart failure. *Eur Heart J*. 2006;27(21):2538-2543.
32. Naughton MT, Lorenzi-Filho G. Sleep in heart failure. *Prog Cardiovasc Dis* 2009;51(4):339-349.
33. Ungkanont K, Areyasathidmon S. Factors affecting quality of life of pediatric outpatients with symptoms suggestive of sleep-disordered breathing. *Int J Pediatr Otorhinolaryngol* 2006;70(11):1945-1948.
34. Bonuck K, Parikh S, Bassila M. Growth failure and sleep disordered breathing: A review of the literature. *Int J Pediatr Otorhinolaryngol* 2006; 70(5):769-778.
35. Astrom CP, Trojaborg W. Effect of growth hormone on human sleep energy. *Clin Endocrinol* 1992;36:241-245.
36. Obal F Jr, Payne L, Kapas L, Opp M, Krueger JM. Inhibition of growth hormone-releasing factor suppresses both sleep and growth hormone secretion in the rat. *Brain Res* 1991;557(1-2):149-153.
37. Davidson JR, Moldofsky H, Lue FA. Growth hormone and cortisol secretion in relation to sleep and wakefulness. *Psychiatry Neurosci* 1991;16(2):96-102.
38. Born J, Muth S, Fehm HL. The significance of sleep onset and slow wave sleep for nocturnal release of growth hormone (GH) and cortisol. *Psychoneuroendocrinology* 1988;13(3):233-243.
39. Olsen KD, Kern EB, Westbrook PR. Sleep and breathing disturbance secondary to nasal obstruction. *Otolaryngol Head Neck Surg* 1981;89(5):804-810.
40. Meurice JC, Marc I, Carrier G, Series F. Effects of mouth opening on upper airway collapsibility in normal sleeping subjects. *Am J Respir Crit Care Med* 1996;153(1):255-259.
41. Oeverland B, Akre H, Skatvedt O. Oral breathing in patients with sleep-related breathing disorders. *Acta Otolaryngol* 2002;122(6):651-654.
42. Quabbe HJ, Gregor M, Bumke-Vogt C, Eckhof A, Witt I. Twenty-four-hour pattern of growth hormone secretion in the rhesus monkey studies including alterations of the sleep/wake and sleep stage cycles. *Endocrinology* 1981;109(2):513-522.
43. Weissbluth M, Davis AT, Poncher J, Reiff J. Signs of airway obstruction during sleep and behavioral, developmental, and academic problems. *J Dev Behav Pediatr* 1983;4(2):119-121.
44. Van Someren VH, Hibbert J, Stothers JK, Kyme MC, Morrison GA. Identification of hypoxaemia in children having tonsillectomy and adenoidectomy. *Clin Otolaryngol Allied Sci* 1990;15(3):263-271.
45. Raskin S, Limme M, Poirrier R. [Could mouth breathing lead to obstructive apnea syndrome. A preliminary study] [article in French]. *Orthod Fr* 2000;71(1):27-35.
46. Huang YS, Guilleminault C, Li HY, Yang CM, Wu YY, Chen NH. Attention-deficit/hyperactivity disorder with obstructive sleep apnea: A treatment outcome study. *Sleep Med* 2007;8(1):18-30.
47. Schredl M, Alm B, Sobanski E. Sleep quality in adult patients with attention deficit hyperactivity disorder (ADHD). *Eur Arch Psychiatry Clin Neurosci* 2007;257(3):164-168.
48. Shur-Fen Gau S. Prevalence of sleep problems and their association with inattention/hyperactivity among children aged 6-15 in Taiwan. *Sleep Res* 2006;15(4):403-414.
49. Philipsen A, Feige B, Hesslinger B, Ebert D, Carl C, Hornyak M, Lieb K, Voderholzer U, Riemann D. Sleep in adults with attention-deficit/hyperactivity disorder: A controlled polysomnographic study including spectral analysis of the sleep EEG. *Sleep* 2005;28(7):877-884.
50. El-Ad B, Lavie P. Effect of sleep apnea on cognition and mood. *Int Rev Psychiatry* 2005;17(4):277-282.
51. Gottlieb DJ, Vezina RM, Chase C, Lesko SM, Heeren TC, Weese-Mayer DE, Auerbach SH, Corwin MJ. Symptoms of sleep-disordered breathing in 5-year-old children are associated with sleepiness and problems in behaviors. *Pediatrics* 2003;112(4):870-877.
52. Rostain AL. Attention-deficit/hyperactivity disorder in adults: Evidence-based recommendations for management. *Postgrad Med* 2008;120(3):27-38.
53. Steinhoff KW. Special issues in the diagnosis and treatment of ADHD in adolescents. *Postgrad Med* 2008;120(3):60-68.
54. Spencer T, Biederman J, Wilens T. Stimulant treatment of adult attention-deficit/hyperactivity disorder. *Psychiatr Clin North Am* 2004;27(2):361-372.
55. Lerner M, Wigal T. Long-term safety of stimulant medications used to treat children with ADHD. *J Psychosoc Nurs Ment Health Serv* 2008;46(8):38-48.
56. Faraone SV, Biederman J, Morley CP, Spencer TJ. Effect of stimulants on height and weight: A review of literature. *J Am Acad Child Adolesc Psychiatry* 2008;47(9):994-1009.
57. Vitiello B. Understanding the risk of using medication for attention deficit hyperactivity disorder with respect to physical and cardiovascular function. *Child Adolesc Psychiatr Clin North Am* 2008;17(2):459-474, ix.
58. Sears J, Patel NC. Development of tics in a thirteen-year-old male following atomoxetine use. *CNS Spectr* 2008;13(4):301-303.
59. Stevenson RD, Wolraich ML. Stimulant medication therapy in the treatment of children with

attention deficit hyperactivity disorder. *Pediatr Clin North Am* 1989;36(5):1183-1197.

60. Upadhyaya HP. Substance used disorders in children and adolescents with attention-deficit/hyperactivity disorder: Implications for treatment and the role of the primary care physician. *Prim Care Companion J Clin Psychiatry* 2008;10(3):311-321.
61. Bright GM. Abuse of medications employed for the treatment of ADHD: Results from a large-scale community survey. *Medscape J Med* 2008;10(5):111.
62. Schubiner H. Substance abuse in patients with attention-deficit hyperactivity disorder: Therapeutic implications. *CNS Drugs* 2005;19(8):643-655.
63. Cohen-Zion M, Ancoli-Israel S. Sleep in children with attention-deficit hyperactivity disorder (ADHD): A review of naturalistic and stimulant intervention studies. *Sleep Med Rev* 2004;8(5):379-402.
64. Greenfeld M, Tauman R, DeRowe A, Sivan Y. Obstructive sleep apnea syndrome due to adenotonsillar hypertrophy in infants. *Int J Pediatr Otorhinolaryngol* 2003;67(10):1055-1060.
65. Rizzi M, Onorato J, Andreoli A, Colombo S, Pecis M, Marchisio P, Morelli M, Principi N, Esposito S, Sergi M. Nasal resistances are useful in identifying children with severe obstructive sleep apnea before polysomnography. *Int J Pediatr Otorhinolaryngol* 2002;65(1):7-13.
66. Wei JL, Mayo MS, Smith HJ, Reese M, Weatherly RA. Improved behavior and sleep after adenotonsillectomy in children with sleep-disordered breathing. *Arch Otolaryngol Head Neck Surg* 2007;133(10):974-979.
67. Zacconi E. [Tonsillectomy and adenoidectomy in children 1 and 2 years] [article in Italian]. *Pediatr Med Chir* 1994;16(3):281-283.
68. Potsic WP, Pasquariello PS, Baranak CC, Marsh RR, Miller LM. Relief of upper airway obstruction by adenotonsillectomy. *Otolaryngol Head Neck Surg* 1986;94(4):476-480.
69. Arrarte J, Lubianca Neto JF, Fischer GB. The effect of adenotonsillectomy on oxygen saturation in children with sleep breathing disorders. *Int J Pediatr Otorhinolaryngol* 2007;71(6):973-978.
70. Avior G, Fishman G, Leor A, Sivan Y, Kaysar N, Derowe A. The effect of tonsillectomy and adenoidectomy on inattention and impulsivity as measured by the Test of Variables of Attention (TOVA) in children with obstructive sleep apnea syndrome. *Otolaryngol Head Neck Surg* 2004;131(4):367-371.
71. Goldstein NA, Post JC, Rosenfeld RM, Campbell TF. Impact of tonsillectomy and adenoidectomy on child behavior. *Arch Otolaryngol Head Neck Surg* 2000;126(4):494-498.
72. Goldstein NA, Fatima M, Campbell TF, Rosenfeld RM. Child behavior and quality of life before and after tonsillectomy and adenoidectomy. *Arch Otolaryngol Head Neck Surg* 2002;128(7):770-775.
73. Leiberman A, Stiller-Timor L, Trasluk A, Tal A. The effect of adenotonsillectomy on children suffering from obstructive sleep apnea syndrome (OSAS): The Negev perspective. *Int J Pediatr Otorhinolaryngol* 2006;70(10):1675-1685.
74. Mitchell RB, Kelly J. Outcomes and quality of life following adenotonsillectomy for sleep-disordered breathing in children. *ORL J Otorhinolaryngol Relat Spec* 2007;69(6):345-348.
75. Gozal D, Pope DW Jr. Snoring during early childhood and academic performance at ages thirteen to fourteen years. *Pediatrics* 2001;107(6):1394-1399.
76. Gozal D. Sleep-disordered breathing and school performance in children. *Pediatrics* 1998;102(3 Pt 1):616-620.
77. Gonzalez Rivera SR, Cormina Isern J, Gay Escoda C. [Respiratory orofacial and occlusion disorders associated with adenotonsillar hypertrophy] [article in Spanish]. *An Otorrinolaringo Ibero Am* 2004;31(3):265-282.
78. Petrou-Amerikanou C, Belazi MA, Daskalopoulou E, Vlachoyiannis E, Daniilidou NV, Papanayiotou PC. Oral findings in patients with obstructive sleep apnea syndrome. *Quintessence Int* 2005;36(4):293-298.
79. Arens R, Marcus CL. Pathophysiology of upper airway obstruction: A developmental perspective. *Sleep* 2004;27(5):997-1019.
80. Carvalho FR, Lentini-Oliveira D, Machado MA, Prado GF, Prado LB, Saconato H. Oral appliances and functional orthopaedic appliances for obstructive sleep apnea in children. *Cochrane Database Syst Rev* 2007;8(3):CD005520.
81. Johal A. Health-related quality of life in patients with sleep-disordered breathing: Effect of mandibular advancement appliances. *J Prosthet Dent* 2006;96(4):298-302.
82. Itzhaki S, Dorchin H, Clark G, Lavie L, Lavie P, Pillar G. The effect of 1-year treatment with a Herbst mandibular advancement splint on obstructive sleep apnea, oxidative stress, and endothelial function. *Chest* 2007;131(3):740-749.
83. Lawton HM, Battagel JM, Kotecha B. A comparison of the Twin Block and Herbst mandibular advancement splints in the treatment of patients with obstructive sleep apnea: A prospective study. *Eur J Orthod* 2005;27(1):82-90.
84. Pirelli P, Saponara M, Guilleminault C. Rapid maxillary expansion in children with obstructive sleep apnea syndrome. *Sleep* 2004;27(4):761-766.

85. Guilleminault C, Quo S, Huynh NT, Li K. Orthodontic expansion treatment and adenotonsillectomy in the treatment of obstructive sleep apnea in prepubertal children. *Sleep* 2008; 31(7):953-957.

86. Villa MP, Malagola C, Pagani J, Montesano M, Rizzoli A, Guilleminault C, Ronchetti R. Rapid maxillary expansion in children with obstructive sleep apnea syndrome: 12-month follow-up. *Sleep Med* 2007;8(2):128-134.

87. Rose E, Schessl J. Orthodontic procedures in the treatment of obstructive sleep apnea in children. *J Orofac Orthop* 2006;67(1):58-67.

88. Cistulli PA, Palmisano RG, Poole MD. Treatment of obstructive sleep apnea syndrome by rapid maxillary expansion. *Sleep* 1998;21(8):831-835.

Manufacturers

Novartis Pharmaceuticals, East Hanover, NJ; 888.644.8585, www.pharma.us.novartis.com

Shire US Inc., Wayne, PA; 800.828.2088, www.adderallxr.com

General Dentistry, January/February 2010 , Volume 58 , Issue 1